

mouth, and sends down a delicate funnel-shaped prolongation, lining the interior of the mantle tube (fig. 3, *t'*.); consequently the branchial siphon is formed of a tubular process of the mantle containing the sphincter muscle (fig. 3, *sph.*), and both lined and covered by a layer of test substance.

The posterior delicate edge of the lining prolongation from the test, ends against the outer side of a ring-like pad which bounds the lower or posterior end of the branchial siphon. This ring bears a circlet of tentacles (fig. 3, *tn.*) on its lower surface, and varies greatly in its size in different forms. In some (*Microcosmus*) it is produced into lobes, forming a partial diaphragm at the entrance to the branchial sac. The circlet of tentacles is followed by a plain area, the præbranchial zone, which is bounded posteriorly by a pair of closely-placed parallel ciliated ridges, the peripharyngeal bands (fig. 3, *p.p.*). Then comes the wall of the branchial sac proper. This is formed by the union of two membranes—an inner, the wall of the pharynx, and lined by endoderm; and an outer, the inner

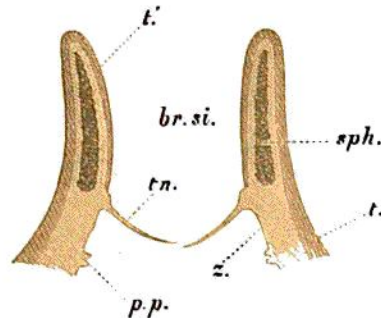


FIG. 3.—Longitudinal section through the Branchial Siphon.

*br. si.*, branchial siphon; *t.*, test; *t'*., prolongation of the test lining siphon; *sph.*, sphincter muscle; *tn.*, tentacle; *z.*, præbranchial zone; *p.p.*, peripharyngeal bands.

wall of a pair of sacs (the atria) formed primitively of involutions of the ectoderm. The two membranes come into contact, coalesce, and then become absorbed at certain points, so as to leave apertures of communication between the interior of the branchial sac and the surrounding atrial sacs or peribranchial cavity. These apertures, which are in the form of narrow slits known as stigmata, are separated by tubes, the walls of which are formed by the two membranes, and the blood which flows in these vessels is thus brought into close relation with the salt water in the branchial sac, the stigmata, and the peribranchial cavity. The stigmata and vessels vary greatly in their size and arrangement, and thus the structure of the branchial sac gives a number of important characteristics for distinguishing genera and species.

There are three chief systems of vessels present in most branchial sacs. First, the transverse vessels which run round the sac horizontally like parallels of latitude on a globe, and separate the different rows of stigmata (fig. 4, *tr.*). These transverse vessels are most constant, and only differ in calibre. In some sacs they are all of one size, while in